



Primigravida with Fetal Malpresentation and Bicornuate Uterus: A Case Report

Christofel Panggabean¹, Muhammad Syauqi Mirza^{2*}, Michelle Putri²

¹Department of Obstetrics and Gynecology, dr. Chasbullah Abdulmajid Regional General Hospital, Bekasi, Indonesia

²Department of Obstetrics and Gynecology, Faculty of Medicine, Universitas Kristen Indonesia, Jakarta, Indonesia

ARTICLE INFO

Keywords:

Bicornuate uterus
Emergency caesarean section
Left oblique presentation
Malpresentation of fetal head

***Corresponding author:**

Muhammad Syauqi Mirza

E-mail address:

saukimirza@gmail.com

All authors have reviewed and approved the final version of the manuscript.

<https://doi.org/10.59345/sjog.v2i1.141>

A B S T R A C T

Introduction: Malpresentation of the fetal head in left oblique presentation is a rare obstetric complication but has the potential to cause birth difficulties. This condition can be worsened by anatomical abnormalities of the uterus such as a bicornuate uterus. **Case presentation:** An 18-year-old primigravida presented with complaints of labor and premature rupture of membranes. Examination revealed malpresentation of the fetal head in left oblique presentation, and further ultrasound examination revealed a possible bicornuate uterus. **Conclusion:** Careful labor management and appropriate surgical intervention, in this case, an emergency caesarean section, resulted in the birth of a healthy baby girl. This case emphasizes the importance of early diagnosis and a multidisciplinary approach in treating complex cases of fetal malpresentation.

1. Introduction

Fetal malpresentation, namely the abnormal position of the fetus in the uterus during delivery, is an obstetric complication that can increase the risk of difficult births and maternal and neonatal morbidity. The prevalence of fetal malpresentation varies depending on the population and gestational age but is generally estimated to occur in approximately 3-4% of all deliveries. Fetal malpresentation can be classified based on the presenting part of the fetus, namely the head, buttocks, shoulders, or other parts of the body. One type of malpresentation that rarely occurs is the malpresentation of the fetal head in the left oblique presentation, where the fetal head is tilted on the left side of the mother's pelvis. This condition

can occur due to various factors, including anatomical abnormalities of the uterus such as a bicornuate uterus, oligohydramnios, multiparity, and fetal abnormalities. A bicornuate uterus is a congenital abnormality that occurs due to impaired fusion of the Müllerian ducts during embryonic development. This condition can affect the position of the fetus in the uterus and cause malpresentation. Malpresentation of the fetal head in the left oblique presentation with a bicornuate uterus is a rare combination that requires special attention in labor management. Malpresentation of the fetal head in the left oblique presentation can cause various birth difficulties, including shoulder dystocia, umbilical cord prolapse, fetal asphyxia, and birth trauma. Therefore, early

diagnosis and appropriate management are essential to ensure maternal and fetal safety. The diagnosis of fetal head malpresentation in the left oblique presentation can be made through physical examination and supporting examinations such as obstetric ultrasound (USG). Physical examination can show the position of the fetal head tilted to the left, while obstetric ultrasound can confirm the diagnosis and identify uterine anatomical abnormalities such as a bicornuate uterus.¹⁻³

Management of fetal head malpresentation in left oblique presentation depends on the gestational age, condition of the mother and fetus, and the presence of other complications. In some cases, an external version can be performed to change the fetal position to a normal cephalic presentation. However, if the external version is unsuccessful or not possible, then a vaginal delivery can be performed with caution or a caesarean section can be considered as a last resort. A bicornuate uterus is a relatively rare congenital abnormality of the uterus, with a prevalence of around 0.1-0.5% of the female population. This disorder occurs due to impaired fusion of the Müllerian ducts during embryonic development, which causes the uterus to have two separate horns. A bicornuate uterus can be classified based on the degree of fusion disorder, namely unicollis bicornuate uterus (one cervix), bicornuate bicollis uterus (two cervixes), and didelphys uterus (two separate uteruses). A bicornuate uterus can affect the position of the fetus in the uterus and cause malpresentation. In addition, a bicornuate uterus can also increase the risk of miscarriage, premature labor, stunted fetal growth, and other birth complications. Therefore, women with a bicornuate uterus require more intensive pregnancy monitoring and individualized labor management. The diagnosis of a bicornuate uterus can be confirmed through supporting examinations such as obstetric ultrasound, hysterosalpingography (HSG), or magnetic resonance imaging (MRI). This examination can show a typical anatomical picture of the uterus, namely two separate uterine horns.^{4,5}

Management of a bicornuate uterus depends on the degree of fusion impairment and the presence of other complications. In some cases, no special intervention

is required during pregnancy and childbirth. However, in cases with a high risk of complications, such as a history of recurrent miscarriage or premature labor, correction surgery may be considered. Malpresentation of the fetal head in the left oblique presentation with a bicornuate uterus is a rare combination that requires special attention in labor management. Early diagnosis and a multidisciplinary approach, including careful ultrasound examination and appropriate surgical intervention, are essential to ensure maternal and fetal safety.^{6,7} Studies are needed to better understand the pathophysiology, risk factors, and optimal management of fetal head malpresentation in left oblique presentation with a bicornuate uterus. With better understanding, it is hoped that more effective prevention and treatment strategies can be developed to improve pregnancy and childbirth outcomes in women with this condition.

2. Case Presentation

An 18-year-old woman, G1POA0 (first pregnancy, never given birth), came to the hospital emergency department with the main complaint of increasingly intense lower abdominal pain and vaginal discharge 17 hours previously. Patients report that abdominal pain feels like contractions that are becoming more frequent and stronger, accompanied by a large amount of clear fluid coming out. The patient also complained of decreased fetal movement in the last few hours. From a more in-depth history, it was discovered that the patient's gestational age was 36 weeks based on the first day of the last menstrual period (LMP). The patient had no history of chronic disease or previous pregnancy complications. The family history of childbirth also did not indicate any congenital abnormalities or significant obstetric complications. General physical examination showed the patient was fully conscious, with no signs of dehydration or shock. Vital signs were within normal limits: blood pressure 110/70 mmHg, pulse 80 beats per minute, respiratory rate 18 breaths per minute, and body temperature 36.5°C. Abdominal examination showed a uterine fundal height of 27 cm, corresponding to a gestational age of 36 weeks. Regular uterine contractions can be felt with a frequency of twice every 15-20 seconds in

10 minutes. Auscultation using Doppler shows the fetal heart rate (FHR) ranges from 135-140 beats per minute but sounds irregular and sometimes weak.

Obstetric examination with a sterile speculum shows the presence of amniotic fluid seeping out of the external cervical ostium. The amniotic fluid appears clear and odorless, indicating that there are no signs of intrauterine infection. Internal examination showed cervical dilation of 2 cm, cervical effacement of 90%, and position of the fetal head tilted to the left. It is palpable that the left parietal bone of the fetus is lower than the right parietal bone, indicating malpresentation of the fetal head in the left oblique presentation. Routine laboratory examinations are carried out to assess the health condition of the mother and fetus. The results of complete blood count, liver function, kidney function, and serum electrolytes were all within normal limits. Blood group and rhesus tests showed that the patient had blood type O positive. Screening tests for infections such as HIV, hepatitis B, and syphilis also showed negative results. An obstetric ultrasound (USG) examination is performed to evaluate the condition of the fetus and placenta. Ultrasound results showed a single live intrauterine fetus with head malpresentation in the left oblique presentation. FHR was confirmed as 135 beats per minute, but there was reduced variability and minimal acceleration, indicating signs of fetal distress. The placenta was identified as implanting at grade II-III in the anterior corpus, with a reduced amniotic fluid index (AFI), of only 1 cm. Fetal biometry showed a biparietal diameter (BPD) of 9.0 cm, abdominal circumference (AC) of 30.6 cm, and femur length (FL) of 6.2 cm, which corresponded to a gestational age of 37 weeks. An interesting finding on ultrasound examination is the suspicion of an anatomical abnormality in the uterus. There is a structure like a uterine horn on the left side of the pelvis, which is lower than the position of the main uterus. This finding raises suspicion of a bicornuate uterus, which is a congenital abnormality in which the uterus has two separate horns. Considering the

gestational age of 37 weeks, history of premature rupture of membranes, malpresentation of the fetal head in left oblique presentation, signs of fetal distress, and suspicion of a bicornuate uterus, the medical team decided to perform an emergency cesarean section. This decision was taken after considering the risks and benefits of various delivery options, as well as the clinical condition of the mother and fetus.

Before surgery, patients are given clear and complete information regarding the surgical procedure, risks and complications that may occur. Patients are also given the opportunity to ask questions and express their concerns. After obtaining approval for medical treatment from the patient and his family, preparations for surgery are carried out quickly and efficiently. During surgery, maternal vital signs and FHR are closely monitored. General anesthesia is administered to ensure patient comfort and safety during the procedure. A lower uterine segment incision was performed, and the baby girl was born with a birth weight of 2,590 grams. The baby was immediately given to the neonatology team for further assessment and treatment. The baby's Apgar score was 7 in the first minute and 8 in the fifth minute, indicating that the baby was in good condition despite previous signs of fetal distress. Examination of the placenta after birth showed that the placenta was in the anterior wall and there were no significant abnormalities. After the separation of the placenta, the uterus is carefully sutured to prevent postpartum hemorrhage. During suturing, a bicornuate uterus with one common cervix was confirmed. The caesarean section was completed without complications, with minimal bleeding. The patient was transferred to the recovery room for further monitoring. After recovering from anesthesia, the patient is transferred to the inpatient ward for postpartum care. The baby is placed in the nursery for further monitoring and care. Mother and baby recovered well with no postoperative complications.

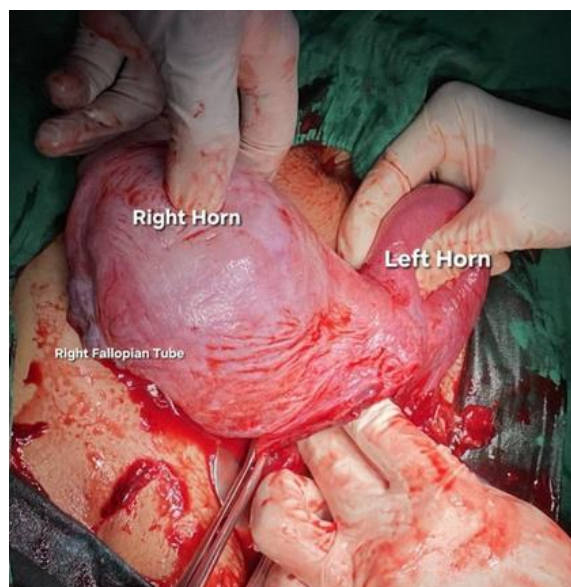


Figure 1. Bicornuate uterus findings during caesarean section.

3. Discussion

To understand how malpresentation of the fetal head in left oblique presentation occurs, it is important to understand the mechanisms of normal labor. At the end of pregnancy, the fetus will enter the mother's pelvic cavity in a flexed position, with the occiput (back of the head) as the lowest part. This position is referred to as vertex presentation or occiput anterior presentation. During labor, the fetal head will experience a series of movements which are known as the delivery mechanism. These movements include descent, flexion, internal rotation, extension, external rotation, and expulsion. These movements allow the fetus' head to adapt to the shape of the mother's pelvis and eventually be born through the birth canal. Malpresentation of the fetal head in left oblique presentation occurs when the fetal head does not enter the pelvic cavity properly, but is in a tilted position on the left side.^{8,9}

The mother's pelvis has an important role in the birthing process. A normal pelvic shape and size will allow the fetal head to enter the pelvic cavity easily and experience the delivery mechanism smoothly. However, in some women, there are anatomical abnormalities in the pelvis which can cause difficulties during the birthing process. A narrow pelvis is a condition where the mother's pelvis is smaller than normal. This can be caused by genetic factors, malnutrition, or bone disease. A narrow pelvis can

make it difficult for the fetal head to enter the pelvic cavity and increase the risk of malpresentation. An asymmetrical pelvis is a condition where the size of the mother's pelvis is not symmetrical between the right and left sides. This can be caused by trauma to the pelvis, bone disease, or congenital abnormalities. An asymmetrical pelvis can cause the fetus' head to tend to be tilted, either to the left or to the right. Anatomical abnormalities in the fetus can also cause malpresentation. Hydrocephalus is a condition where there is a buildup of fluid in the fetus's brain. This can cause the fetal head to be larger than normal and difficult to enter the pelvic cavity. Fetal neck tumors can make it difficult for the fetal head to move and rotate into an optimal position for delivery.¹⁰⁻¹²

The placenta is an organ that functions to provide nutrition and oxygen to the fetus during pregnancy. Normally, the placenta is located at the top of the uterus. However, in some cases, the placenta can be located at the bottom of the uterus (placenta previa) or even cover part or all of the birth canal (placenta previa totalis). Placenta previa can prevent the fetus' head from entering the pelvic cavity and increase the risk of malpresentation. Placenta previa totalis is a more serious condition, where the placenta covers the entire birth canal. This condition can make vaginal delivery impossible and require a caesarean section. Polyhydramnios is a condition where there is excess amniotic fluid in the uterus. Polyhydramnios can

cause the fetus to move more easily in the uterus and not be able to maintain an optimal position for delivery. This can increase the risk of malpresentation, including malpresentation of the fetal head in left oblique presentation.^{13,14}

In women who have given birth several times (multiparous), the muscles of the abdomen and uterus may become weaker. This can cause the fetus to move more easily in the uterus and not be able to maintain an optimal position for delivery. Multiparity is a risk factor for malpresentation. Apart from the factors above, there are several other factors that can also increase the risk of malpresentation of the fetal head in the left oblique presentation. In twin pregnancies, the fetus's movement space is more limited, so the risk of malpresentation is higher. In premature pregnancy, the fetus is not mature enough to enter the pelvic cavity properly and tends to be in a position that is not optimal for delivery. Uterine tumors can block the entry of the fetal head into the pelvic cavity and increase the risk of malpresentation. Malpresentation of the fetal head in the left oblique presentation is a complex condition and can be caused by various factors. Understanding the pathophysiology of this malpresentation is very important to determine the appropriate diagnosis and management. With proper treatment, most cases of fetal head malpresentation in left oblique presentation can be treated well, so that the mother and fetus can go through the birth process safely.^{15,16}

A bicornuate uterus, or a two-horned uterus, is a congenital abnormality that is relatively rare but has a significant impact on pregnancy and childbirth. This condition is characterized by the presence of two uterine cavities that are partially or completely separated, with one cervix. These anatomical variations can affect the position of the fetus in the uterus, increase the risk of malpresentation, and cause birth complications. A bicornuate uterus occurs due to the failure of complete fusion of the Müllerian ducts during embryological development. The Mullerian duct is an embryonic structure that will later develop into the uterus, fallopian tubes, cervix, and upper third of the vagina. In a bicornuate uterus, the two Müllerian ducts fail to fuse completely,

resulting in the formation of two separate uterine cavities. The severity of a bicornuate uterus varies, from a mild form with a slight indentation of the uterine fundus to a severe form with the two uterine cavities almost completely separated. More severe forms tend to cause more significant problems during pregnancy and delivery. The smaller uterine cavity in a bicornuate uterus provides more limited movement space for the fetus. This can make it difficult for the fetus to move and rotate into an optimal position for delivery. The asymmetrical shape of the uterus in a bicornuate uterus can cause the fetus to become unstable. The fetus may have difficulty maintaining a head-down position (vertex presentation) and tends to be in a breech, transverse, or sideways position. A bicornuate uterus increases the risk of malpresentation, namely an abnormal position of the fetus during delivery. Malpresentations that often occur in a bicornuate uterus include breech presentation, transverse presentation, and oblique presentation. In some cases, a bicornuate uterus can cause stunted fetal growth (intrauterine growth restriction/IUGR). This is caused by limited space for the fetus to move and less than optimal blood supply to the placenta.^{16,17}

A bicornuate uterus increases the risk of preterm labor, namely labor that occurs before 37 weeks of gestation. This is caused by ineffective uterine contractions and irritation of the cervix due to abnormal fetal position. Dystocia is difficult or abnormal labor. A bicornuate uterus can cause dystocia due to uncoordinated uterine contractions, fetal malpresentation, or obstruction of the birth canal by the uterine septum (the dividing wall between the two uterine cavities). Although rare, a bicornuate uterus increases the risk of uterine rupture, which is the tearing of the uterine wall during labor. This can occur due to excessive uterine contractions or strong pressure from the fetus on the thin uterine wall. A bicornuate uterus can also increase the risk of postpartum bleeding due to ineffective uterine contractions or the presence of residual placental tissue remaining in the uterus. The diagnosis of a bicornuate uterus can be confirmed through supporting examinations such as ultrasonography

(USG), hysterosalpingography (HSG), or magnetic resonance imaging (MRI). Ultrasound is the most frequently used method because it is non-invasive and can provide a clear picture of the shape of the uterus. Management of a bicornuate uterus depends on the severity of the abnormality and the symptoms experienced by the patient. In mild and asymptomatic cases, no special intervention is needed. However, in cases that are severe or cause problems during pregnancy, surgical procedures such as metroplasty (uterine reconstruction surgery) may be needed to improve the shape of the uterus and increase the chances of a successful pregnancy. Women with a bicornuate uterus who become pregnant require closer monitoring during pregnancy. This aims to detect early complications that may occur, such as malpresentation, stunted fetal growth, or premature labor. Pregnancy monitoring includes regular ultrasound examinations to assess fetal growth and development, as well as the position of the fetus in the uterus. If malpresentation or other complications are detected, the doctor will consider appropriate action, such as an external version or caesarean section. A bicornuate uterus is a congenital abnormality that can affect the position of the fetus in the uterus and increase the risk of malpresentation and birth complications. Nonetheless, with early diagnosis, careful pregnancy monitoring, and appropriate management, most women with a bicornuate uterus can have a safe and healthy pregnancy and delivery.^{17,18}

A bicornuate uterus, or a two-horned uterus, is a congenital abnormality of the uterus characterized by the presence of two uterine cavities that are partially or completely separated. This condition occurs due to the failure of complete fusion of the Müllerian ducts during embryological development. Although a bicornuate uterus can vary in severity, in general, this abnormal uterine shape can increase the risk of fetal malpresentation, including malpresentation of the fetal head in the left oblique presentation. Anatomically, a bicornuate uterus has two separate uterine cavities, each with one fallopian tube and one ovary. These two cavities can be fused at the bottom to form one cervix (uterus bicornuate unicollis) or have

two separate cervixes (uterus bicornuate bicollis). The severity of this abnormality varies, from a uterus that is almost completely separated to a uterus that only has a slight curve at the top. The abnormal shape of the uterus in a bicornuate uterus can affect the position of the fetus in the uterus. The space available for the fetus becomes more limited, making it difficult for the fetus to move and rotate into an optimal position for delivery. In addition, uneven uterine walls in a bicornuate uterus can interfere with the fetus' ability to make the rotational movements necessary to achieve cephalic presentation.^{18,19}

In a bicornuate uterus, the smaller and narrower uterine cavity can make it difficult for the fetal head to enter the pelvic cavity properly. This can cause the fetus' head to be in a tilted position, such as in the left oblique presentation. Apart from that, a bicornuate uterus can also affect uterine contractions during labor. Ineffective uterine contractions can cause labor to be longer and more difficult, thereby increasing the risk of malpresentation. The diagnosis of a bicornuate uterus can be confirmed through several examination methods, including: Ultrasonography (USG): Ultrasound is the most frequently used supporting examination to diagnose a bicornuate uterus. Ultrasound can show an abnormal shape of the uterus, such as the presence of two separate uterine cavities. Hysterosalpingography (HSG): HSG is a radiological examination that uses a contrast agent to assess the shape of the uterus and fallopian tubes. HSG can provide a clearer picture of the anatomy of the uterus compared to ultrasound. Magnetic resonance imaging (MRI): MRI is the most accurate supporting examination for diagnosing a bicornuate uterus. MRI can provide a three-dimensional image of the anatomy of the uterus, so it can help doctors determine the severity of this abnormality. A bicornuate uterus can cause various complications during pregnancy and delivery, including: Fetal Malpresentation: As previously explained, a bicornuate uterus can increase the risk of fetal malpresentation, including malpresentation of the fetal head in left oblique presentation. Premature labor: A bicornuate uterus can cause preterm labor, which is labor that occurs before 37 weeks of

gestation. Premature rupture of membranes (PROM): A bicornuate uterus can cause PROM, which is the rupture of the membranes before labor begins. Antepartum Bleeding: A bicornuate uterus can cause antepartum hemorrhage, which is bleeding that occurs before delivery. Placental Retention: A bicornuate uterus can cause retained placenta, which is a condition where the placenta does not separate from the uterine wall after delivery.¹⁶⁻¹⁸

Management of a bicornuate uterus in pregnancies with malpresentation depends on the gestational age, condition of the mother and fetus, and the severity of the malpresentation. The external version is an action to change the position of the fetus from a breech or transverse position to a head position. This action can be carried out at 36-37 weeks of gestation. Caesarean section is the main choice for delivery in cases of malpresentation of the fetal head in left oblique presentation with a bicornuate uterus. This is done to avoid the risk of birth complications, such as shoulder dystocia, uterine rupture, and fetal distress. Early detection of a bicornuate uterus is very important to prevent complications during pregnancy and childbirth. Routine ultrasound examinations during pregnancy can help doctors detect abnormalities in the uterus. If a bicornuate uterus is detected, doctors can monitor the pregnancy more closely and plan a safe delivery. Appropriate management of cases of bicornuate uterus with fetal malpresentation is very important to ensure the safety of the mother and fetus. Caesarean section is the main choice for delivery in this case. With proper treatment, most women with a bicornuate uterus can give birth to healthy babies.^{19,20}

4. Conclusion

Malpresentation of the fetal head in the left oblique presentation with a bicornuate uterus is a rare combination that requires special attention in labor management. Early diagnosis and a multidisciplinary approach, including careful ultrasound examination and appropriate surgical intervention, are essential to ensure maternal and fetal safety.

5. References

1. American College of Obstetricians and Gynecologists. Practice Bulletin No. 194: Fetal Malpresentation. *Obstet Gynecol.* 2018; 132(3): e112-e125.
2. Chan BC, Tsoi E. The management of fetal malpresentation. *Best Pract Res Clin Obstet Gynaecol.* 2019; 57: 39-51.
3. Grivell RM, Dodd JM, Crowther CA. Antenatal interventions for breech presentation. *Cochrane Database Syst Rev.* 2018; (9).
4. Hofmeyr GJ, Kulier R. External cephalic version for breech presentation at term. *Cochrane Database Syst Rev.* 2018; (9).
5. Neilson JP. External cephalic version for breech presentation before term. *Cochrane Database Syst Rev.* 2019; (9).
6. Penna L, O'Brien P. Breech presentation: Delivery and its complications. *Seminars Fetal Neonatal Med.* 2018; 23(4): 237-43.
7. Dutta S, Bhattacharya S. Uterine anomalies: a comprehensive review. *J Hum Reprod Sci.* 2020; 13(2): 99-108.
8. Grimbizis GF, Campo R, Tarlatzis BC. Uterine anomalies: Classification, diagnosis, and management. *Fertil Steril.* 2021; 115(1): 7-16.
9. Ludwin A, Ludwin I, Ludwin D. Uterus bicornis unicollis: a review of the literature. *J Obstet Gynaecol Res.* 2022; 48(3): 544-53.
10. Nahum GG. Uterine anomalies: How common are they, and what is their distribution among subtypes? *J Minim Invasive Gynecol.* 2019; 26(4): 704-10.
11. Saravelos HG, Cocksedge KA, Li TC. Prevalence and diagnosis of congenital uterine anomalies in women with reproductive failure: a critical appraisal. *Hum Reprod Update.* 2018; 24(5): 549-63.
12. Chan YY, Jayaprakasan K, Zamora J, Thornton JG, Raine-Fenning N, Coomarasamy A. The prevalence of congenital uterine anomalies in unselected and high-risk populations: a systematic review and meta-analysis. *Hum Reprod Update.* 2019; 25(4): 410-23.

13. Deutch TD, Abulafia O, Sherer DM. Congenital uterine anomalies: Impact on pregnancy outcomes. *J Ultrasound Med.* 2020; 39(6): 1143-53.
14. Gynecology and Obstetrics, A. C. o. Practice Bulletin No. 226: Cesarean Delivery. *Obstet Gynecol.* 2021; 138(1): e1-e20.
15. Knight M. Cesarean delivery. *Am Fam Physician.* 2020; 101(11): 661-8.
16. Menon R. Cesarean delivery: an overview. *World J Obstet Gynecol.* 2018; 6(2): 38-45.
17. National Institutes of Health. Cesarean birth. 2023.
18. World Health Organization. WHO recommendations: Intrapartum care for a positive childbirth experience. Geneva: World Health Organization. 2018.
19. American College of Obstetricians and Gynecologists. Cesarean Delivery on Maternal Request. Committee Opinion No. 824. *Obstet Gynecol.* 2022; 140(2): e147-e155.
20. Betrán AP, Torloni MR, Zhang JJ, Gülmezoglu AM. WHO statement on caesarean section rates. *BJOG: Int J Obstet Gynaecol.* 2018; 125(13): 1619-20.